

## ANOMALOUS DRAINAGE OF THE INFERIOR VENA CAVA AND PULMONARY VEINS: A RARE CASE REPORT

### CASE REPORT

**Authors:** Stéfani Mariani - Universidade Federal de Ciências da Saúde de Porto Alegre – E-mail: stefani.mariani22@gmail.com;

Luciana Rosés Rizzon - Universidade Federal de Ciências da Saúde de Porto Alegre - E-mail: lucianarrizzon@gmail.com;

Nicole Sciarra Mandelli - Santa Casa de Porto Alegre - E-mail: nicolesmandelli@gmail.com;

Ruhana Dalla Costa - Santa Casa de Porto Alegre - E-mail: ruhanadalla@gmail.com.

**Corresponding author:** Stéfani Mariani - Universidade Federal de Ciências da Saúde de Porto Alegre – E-mail: stefani.mariani22@gmail.com

**Keywords:** Vena Cava, Inferior; Pulmonary Veins; Heart Defects, Congenital

**URL:** <https://brad.org.br/article/4430/pt-BR/anomalous-drainage-of-the-inferior-vena-cava-and-pulmonary-veins--a-rare-case-report>

**DOI:** 10.5935/2965-1980.2024v3e20240042

### ABSTRACT

Total anomalous pulmonary venous connection (TAPVC) and drainage of the inferior vena cava into the left atrium are rare congenital heart diseases. In this case report, we present a newborn patient with the rare combination of these two conditions, diagnosed by chest computed tomography angiography (CTA).

### CLINICAL HISTORY

Female patient, on the first day of her life, presented with vomiting, cyanosis and desaturation. Empirical treatment for neonatal sepsis was initiated, without improvement. A chest CTA was performed, which showed the combination of total anomalous drainage of the pulmonary veins and drainage of the inferior vena cava into the left atrium.

### IMAGING FINDINGS

A chest CTA showed non-obstructive supracardiac TAPVC, subtype Ia, which occurs when all pulmonary veins converge into a vertical vein, which drains into the left brachiocephalic vein and then into the superior vena cava, which converges into the right atrium (Figures 1 and 2). An ostium secundum interatrial communication was also demonstrated, an essential condition for life in this congenital heart disease (Figure 3). In association with these findings, there was

drainage of the inferior vena cava into the left atrium (Figure 4). In the schematic figure it is possible to observe the combination of these changes (Figure 5).

### DISCUSSION

Anomalous pulmonary venous drainage is a rare congenital malformation, which accounts for less than 1% of all congenital heart defects [1]. Defects can be partial, when only part of the pulmonary venous circulation has anomalous drainage, or complete, when none of the pulmonary veins drain into the left atrium. Prevalence varies between 0.6 to 1.2 cases for every 10,000 live births [2-4]. The supracardiac subtype is the most common, occurring in approximately 30-40% of cases [5], characterized by the final drainage of all pulmonary veins into the superior vena cava. In these cases, atrial septal defect (ASD) is an essential condition. Aberrant drainage of the inferior vena cava (IVC) into the left atrium is also a rare condition and was first described in the literature in 1955 [6]. TAPVC may be associated with several syndromes [5]. There is only one case described in the literature by Lamb et. al. in 1987 of the association between non-obstructive supracardiac TAPVC and anomalous venous return from the IVC to the left atrium [7]. Muir and Prathap, in 1965, described an association between drainage from the IVC to the left atrium and TAPVC, however, with the infracardiac

subtype and splenic agenesis [8]. The clinical presentation varies according to the degree of obstruction of the pulmonary vessels. This anatomical change causes volume overload of the right ventricle and pulmonary circulation resulting in congestion and heart failure, as well as generating arterial desaturation due to the mixing of systemic and pulmonary venous blood in the right atrium, through the ASD [9]. Diagnosis is usually made by transthoracic echocardiography. Chest CTA or cardiac magnetic resonance can also be performed for better anatomical characterization [5,10]. Surgical correction is the treatment of choice and should be performed as soon as possible. To our knowledge, this is the second published case in the medical literature describing the association of TAPVC with anomalous drainage from the IVC to the left atrium. In a multidisciplinary meeting, the surgical approach was decided, with redirection of the pulmonary veins to the left atrium and the IVC to the right atrium, as well as closure of the ASD. The patient evolved favorably, being discharged asymptomatic, 18 days after hospital admission.

## DIFFERENTIAL DIAGNOSIS

- Subtype Ib supracardiac total pulmonary anomalous venous connection;
- Infracardiac total pulmonary anomalous venous connection;
- Partial anomalous pulmonary venous connection.

## TEACHING POINTS

In this case, we learned the importance of each diagnostic imaging method in assessing vascular changes. Despite the correct description of these anatomical alterations, the echocardiogram had limitations in the acoustic window, making it necessary to complement it with CTA. In addition to providing a 3D visualization of the entire heart and the major mediastinal vessels, CTA offers the possibility of selecting the imaging acquisition time after the injection of contrast. The difference in density in Hounsfield Units, represented by the volume of contrast in each of the cardiac compartments, allows us to infer whether there is communication between them, resulting in additional data for a better anatomical vascular characterization.

## REFERENCES

- 1 - Egbe A, Uppu S, Stroustrup A, Lee S, Ho D, Srivastava S. Incidences and sociodemographics of specific congenital heart diseases in the United States of America: an evaluation of hospital discharge diagnoses. *Pediatr Cardiol.* 2014 Aug;35(6):975-82. DOI: 10.1007/s00246-014-0884-8. Epub 2014 Feb 22. PMID: 24563074;
- 2 - Prakash A, Jhalani I, Darbari A, Kumar A. A Case of Late Presentation of Supracardiac Total Anomalous Pulmonary Venous Connection in an Adult. *J Cardiovasc Echogr.* 2023 Oct-Dec;33(4):202-205. DOI: 10.4103/jcecho.jcecho\_62\_23. Epub 2024 Feb 26. PMID: 38486695; PMCID: PMC10936703.
- 3 - Reller MD, Strickland MJ, Riehle-Colarusso T, Mahle WT, Correa A. Prevalence of congenital heart defects in metropolitan Atlanta, 1998-2005. *J Pediatr.* 2008 Dec;153(6):807-13. DOI: 10.1016/j.jpeds.2008.05.059. Epub 2008 Jul 26. PMID: 18657826; PMCID: PMC2613036.
- 4 - Hoffman JI, Kaplan S. The incidence of congenital heart disease. *J Am Coll Cardiol.* 2002 Jun 19;39(12):1890-900. DOI: 10.1016/s0735-1097(02)01886-7. PMID: 12084585.
- 5 - Vanderlaan RD, Caldarone CA. Surgical Approaches to Total Anomalous Pulmonary Venous Connection. *Semin Thorac Cardiovasc Surg Pediatr Card Surg Annu.* 2018 Mar;21:83-91. DOI: 10.1053/j.pcsu.2017.11.010. PMID: 29425529;
- 6 - Burri H, Vuille C, Sierra J, Didier D, Lerch R, Kalangos A. Drainage of the inferior vena cava to the left atrium. *Echocardiography.* 2003 Feb;20(2):185-9. DOI: 10.1046/j.1540-8175.2003.03009.x. PMID: 12848686.
- 7 - Lamb RK, Qureshi SA, Patel RG, Hamilton DI. Anomalous drainage of inferior vena cava to left atrium in association with total anomalous pulmonary venous drainage. *Thorax.* 1987 Nov;42(11):907-8. DOI: 10.1136/thx.42.11.907. PMID: 3424277; PMCID: PMC461023.
- 8 - Muir Cs, Prathap K. Co-Existent Total Anomalous Pulmonary Venous Drainage Into Portal Vein, Drainage Of Left-Sided Inferior Vena Cava Into Left Atrium, And Splenic Agenesis. *Thorax.* 1965 May;20(3):254-60. DOI: 10.1136/thx.20.3.254. PMID: 14292434; PMCID: PMC1018931.
- 9 - Behrendt DM, Aberdeen E, Waterson DJ, Bonham-Carter RE. Total anomalous pulmonary venous drainage in infants. I. Clinical and hemodynamic findings, methods, and results of operation in 37 cases. *Circulation.* 1972 Aug;46(2):347-56. DOI: 10.1161/01.cir.46.2.347. PMID: 5046028.
- 10 - Kimura, L. Y., Fernandes, G. S. dos S., Nobrega, K. T. de M., Gabure, L. A. G., Cattani, C. A. M., Silva, J. P. da ., & Furlanetto, B. H. S.. (2010). Angiotomografia com múltiplos detectores no diagnóstico de drenagem venosa pulmonar anômala: experiência inicial. *Radiologia Brasileira*, 43(6), 347–353. <https://doi.org/10.1590/S0100-39842010000600004>.

FIGURES

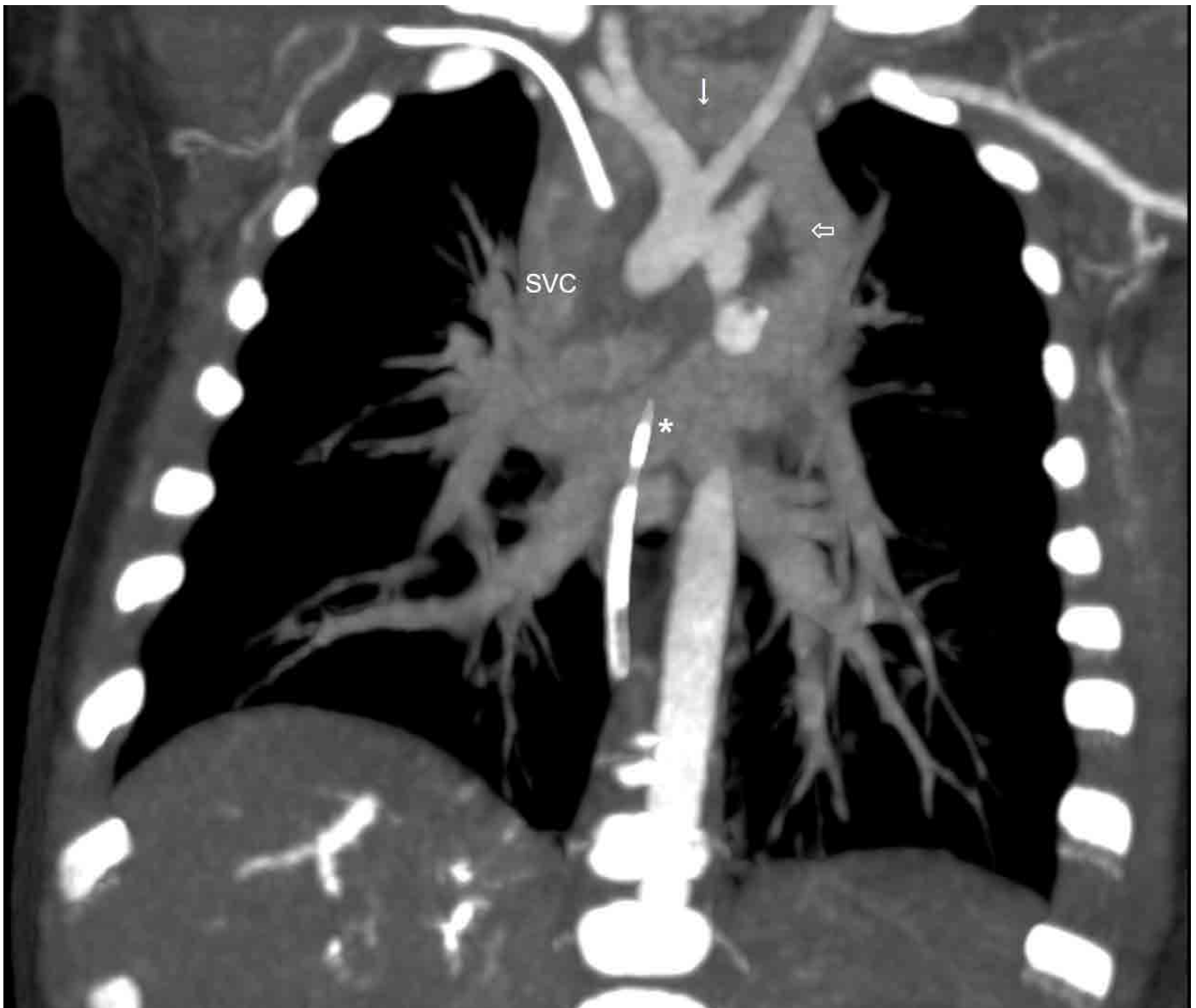

FIGURE 1: A Chest CTA showed non-obstructive supracardiac TAPVC, subtype Ia: all pulmonary veins (\*) converge into a vertical vein (empty arrow), which drains into the left brachiocephalic vein (arrow) and then into the superior vena cava (SVC).

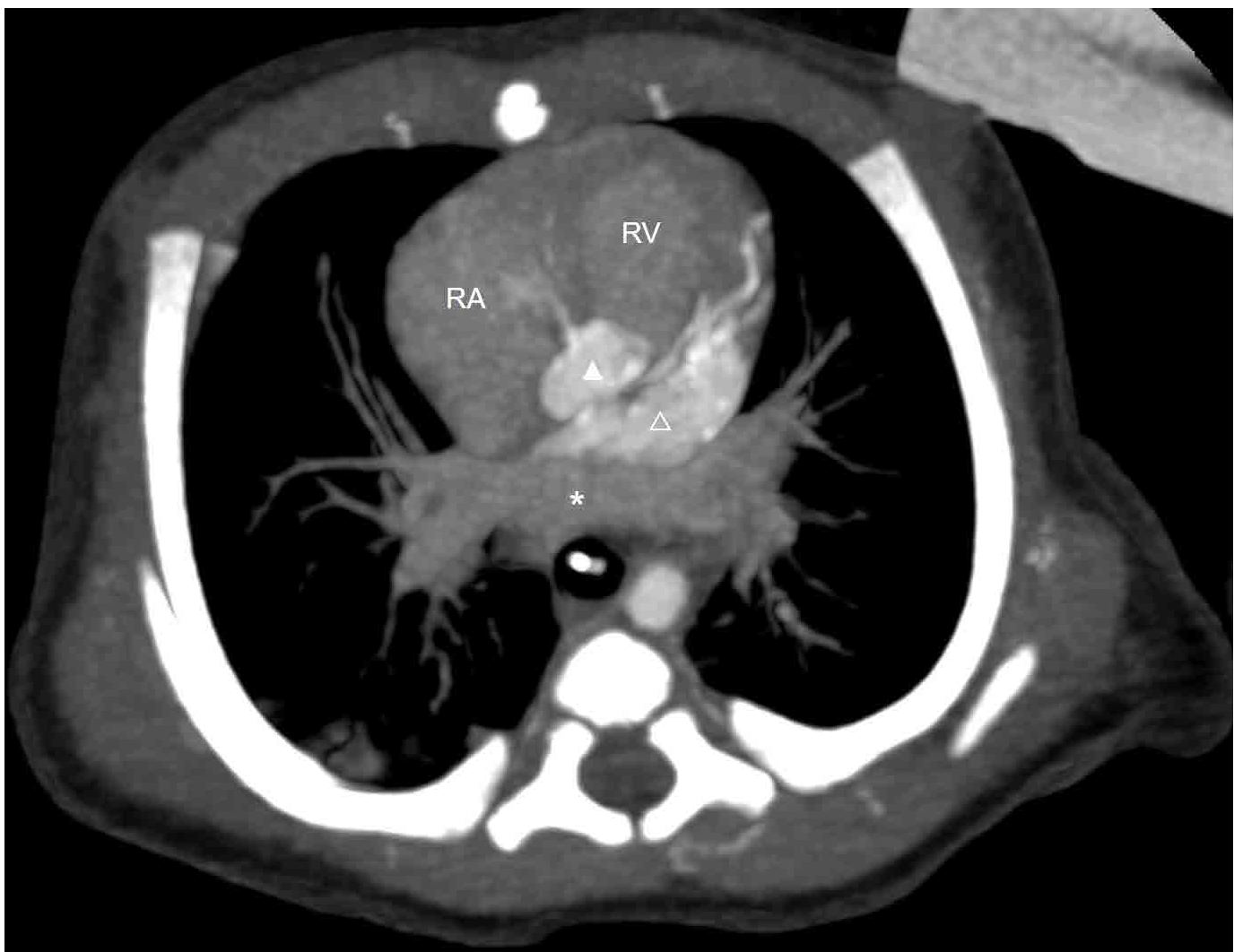


FIGURE 2: A Chest CTA showed that all pulmonary veins (\*) are not connected with the left atrium (empty arrowhead). RV = right ventricle. RA = right atrium. Arrowhead = aorta.

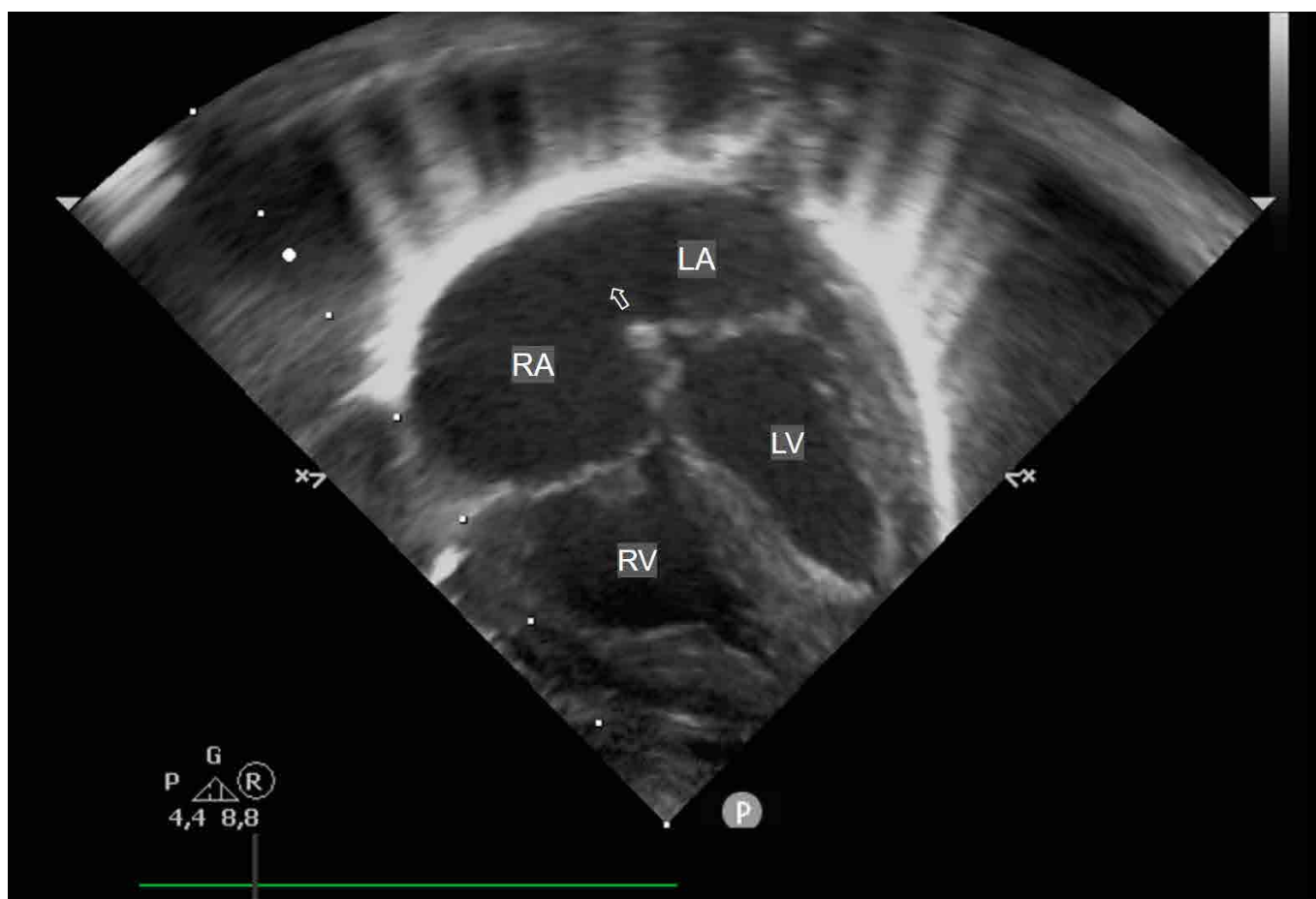
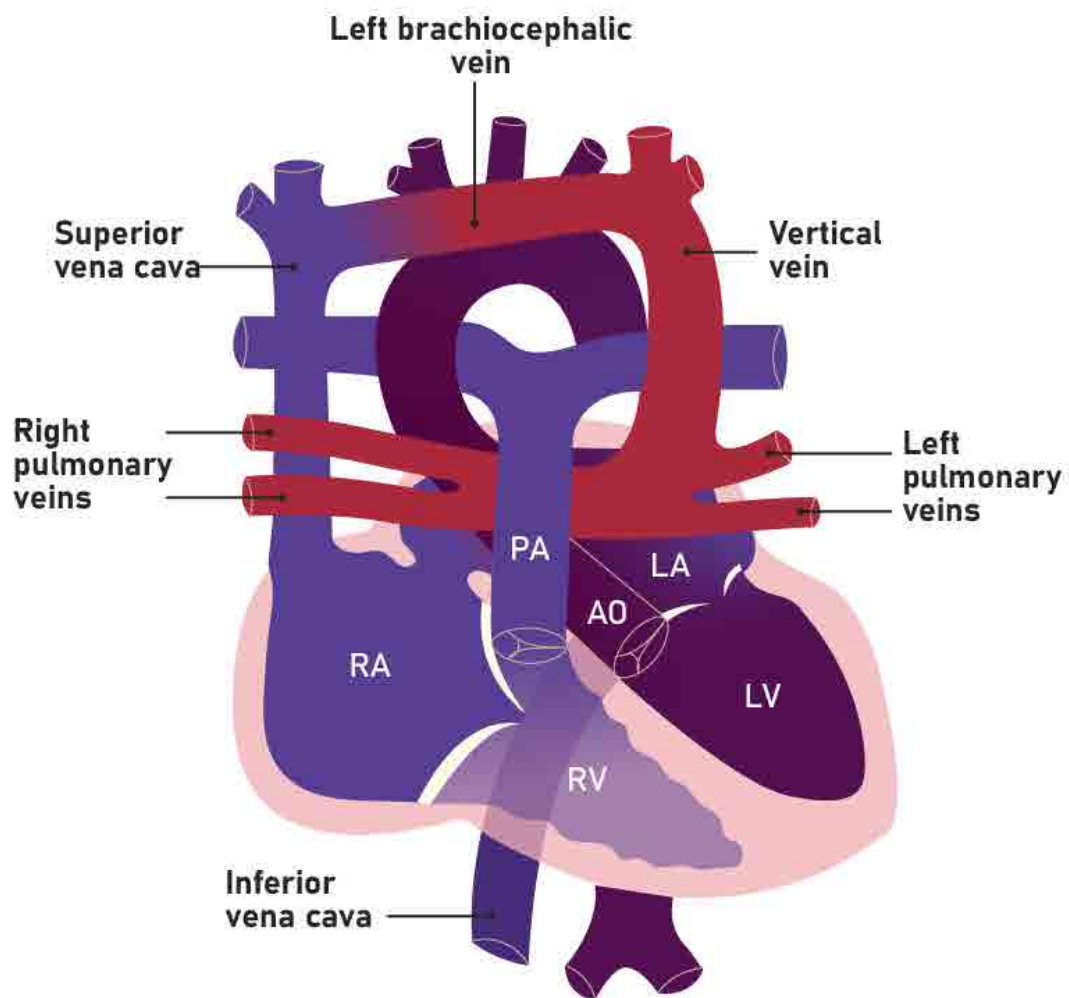


FIGURE 3: Transthoracic echocardiography showed interatrial communication due to ostium secundum (empty arrow). RA = right atrium. LA = left atrium. RV = right ventricle. LV = left ventricle.

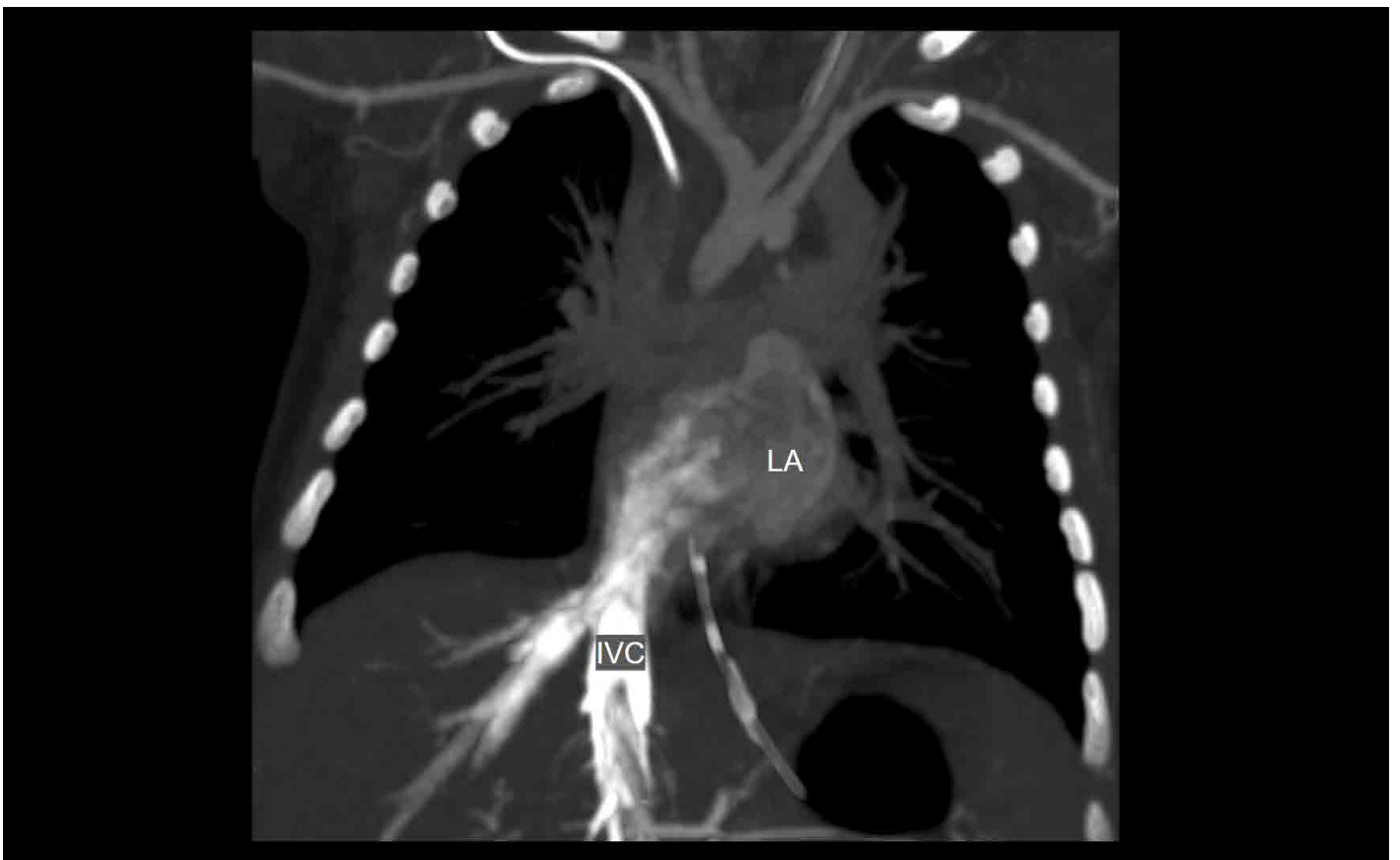

FIGURE 4: A Chest CTA showed the drainage of the inferior vena cava (IVC) into the left atrium (LA).



**FIGURE 5:** In the schematic figure it is possible to observe the combination of all the changes: TAPVC and anomalous drainage of the IVC into the left atrium. RA = right atrium. LA = left atrium. RV = right ventricle. LV = left ventricle. AO = aorta. PA = pulmonary artery.